

KRF Clinical Practice Guidelines in Keloid Disorder (KRF Guidelines®)

Scalp Keloids

Version 1.2018 — November 30, 2018

Author: Michael H. Tirgan, MD

KeloidResearchFoundation.org

Michael H. Tirgan, MD (Chair)

Keloid Research Foundation
New York, USA

We, the undersigned, fully endorse and support the recommendations and content of this Guideline and have adapted this into our own medical practices.

Raul Caceres, MD

Plastic Surgery
New York, USA

Patricia Danielsen, MD, PhD

Department of Dermatology
University Hospital of Copenhagen
Copenhagen
Denmark

Reza Ghohestani, MD, PhD

Texas Institute of Dermatology
San Antonio, Texas
USA

Prof. Dr. Jürg Hafner

Division of In-Hospital Dermatology &
Surgical Dermatology
Department of Dermatology
University Hospital of Zurich
Zurich, CH-8091
Switzerland

Tamara Maravic-Gidakovic, MD

Dermatology and Venereology
Dermanova
Belgrade
Serbia

Tae Hwan Park, MD, PhD

Department of Plastic and
Reconstructive Surgery
CHA University College of Medicine
59 Yatap-ro, Bundang-gu, Seongnam,
Gyeonggi 13496,
Korea

The KRF Guidelines® are statements of evidence and consensus of the authors regarding their views of currently accepted approaches to treatment. Any clinician seeking to apply or consult the KRF® Guidelines is expected to use independent medical judgement in the context of individual clinical circumstances to determine any patient's care or treatment. The Keloid Research Foundation® (KRF®) makes no representations or warranties of any kind regarding their content, use or application and disclaims any responsibility for their application or use in any way. The KRF® Guidelines are copyrighted by Keloid Research Foundation. All rights reserved. The KRF Guidelines and the illustrations herein may not be reproduced in any form without the express written permission of KRF®. ©2018.

SUMMARY

DIAGNOSIS

Diagnosis of scalp keloid lesions is based on the clinical history as well as the appearance of the skin lesion. A biopsy is almost never indicated to establish the diagnosis.

GROUPING OF SCALP KELOIDS

For purposes of this Guideline, scalp keloids are grouped into 4 different categories:

1. *Early-stage* disease presenting with protruding papules (acne keloidalis) - often in occipital skin – or linear or nodular lesions (<2 cm - *Scalp Stage IA*) [1].
2. *Locally-advanced - organized patch* presenting with conglomeration of papules and formation of keloid patches (2-10 cm – *Scalp Stage IB-IC*).
3. *Superficially-spreading / multifocal* disease presenting with large areas of scalp involvement (> 10 cm – *Scalp Stage IIA and above*).
4. *Tumoral* disease presenting with bulky tumor masses.

TREATMENT

Topical high-potency steroid lotions should be prescribed to all patients presenting with early-stage or locally-advanced disease.

Contact cryotherapy (See KRF Guideline - Cryo) is the preferred and primary method of destruction of all early-stage and locally-advanced scalp keloid lesions. Using spray cryotherapy or intra-lesional cryotherapy is not advised.

Rationale for the use of cryotherapy

- a. Cryotherapy is an effective method of treatment for protruding scalp keloids.
- b. As opposed to surgery, cryotherapy does not cause worsening of keloids.
- c. As opposed to surgery, adjuvant radiation therapy is unnecessary after cryotherapy.

Cryotherapy should be repeated once every 4-8 weeks, depending on the size of the treated lesions. Once all visible keloid lesions are brought under control, patients should be followed up clinically to detect any potential early recurrent disease. All patients should be instructed to examine their scalp on a regular basis and return for treatment at the earliest sign of a potential recurrence or development of new lesions.

TREATMENTS TO AVOID

Surgery shall NOT be used in treatment of scalp keloids. Surgical intervention is a known cause for worsening of keloids [1, 2]. This is also documented in the cases presented in this Guideline (Figures 15-18).

Surgical excision may ONLY be considered in cases of massive scalp keloids and shall only be done in coordination with a specialist physician who is familiar with keloid disorder and is able to implement adjuvant medical treatments to prevent recurrence (see below).

Radiation therapy shall NOT be used in treatment of scalp keloids. Radiation therapy carries a known risk of causing secondary malignancies [3,4].

Lasers shall NOT be used in treatment of scalp keloids. This intervention may result in worsening of keloids [5].

Intra-lesional Triamcinolone (ILT) shall not be used in treatment of scalp keloids. This intervention is known to cause worsening of keloids [6].

OVERVIEW

This KRF Guideline was developed with the aim to provide:

1. General discussion of scalp keloids.
2. Natural history of scalp keloids.
3. Classification system for scalp keloids.
4. Recommendations for treatment and follow-up.

Keloid involvement of the scalp skin is fairly uncommon and is seen in about five percent of all patients with keloid disorder. In a recent analysis of data from 1,088 consecutive keloid patients seen by the author in his keloid specialty practice, there were only 54 patients with scalp keloids. Scalp involvement is strikingly gender and race-specific and is almost exclusively seen in black males. Among 54 patients seen by the author, 51 were male and 49 were African American. All three female patients had extensive keloid involvement of their skin. One female patient was Asian and had developed a keloid at the site of a prior surgery on her occipital scalp. Two African American females in this cohort had developed keloid tumors in their occipital skin (Figure 14).

Involvement of the scalp as the only site of keloid disorder was observed in almost half of this cohort. Twenty five cases (47% of the 54 patients) had keloid lesion(s) elsewhere on their skin.

Like other keloids, the clinical presentation, size and shape of skin lesions of the scalp varies from patient to patient. In their early stages, scalp lesions are small and few in number. With passage of time, the lesions grow in size and number and spread to involve larger areas of the scalp. To the best of the author's knowledge, there has never been a proper method for classification of scalp keloids.

MORPHOLOGICAL CLASSIFICATION OF SCALP KELOIDS

The most common morphological subtypes of scalp keloids covered in this KRF Guideline are listed below. Accordingly, all of the 54 patients mentioned earlier in this chapter have been assigned to one of the following categories.

- **Early-stage (less than 2 cm – Scalp Stage IA)**
 - Papular
 - Linear
 - Nodular
- **Locally-advanced / organized patch (2-10 cm – Scalp Stage IB-IC)**
 - Flat
 - Papular
 - Nodular
- **Superficially-spreading / multifocal (> 10 cm – Scalp Stage IIA and above)**

- Flat
- Papular
- Multi-Nodular

○ **Tumoral**

- Tumoral - IB (2-5 cm – bulky tumor mass, Scalp Stage IB)
- Tumoral - semi-massive (5-10 cm – bulky tumor mass, Scalp Stage I C)
- Tumoral - massive (>10 cm – bulky tumor mass, Scalp Stage IIA and above)

The system proposed here may not be complete and may not address every case of scalp keloid.

PATTERN OF SCALP INVOLVEMENT

Involvement of scalp in the majority of keloid patients is non-homogenous and multifocal. Most patients present with several lesions that are of different in their shapes and size and are scattered throughout their scalp.

The morphological classification introduced here is based on the appearance of largest segment of the scalp keloid lesion(s). A patient with tumoral keloid may also have a small cluster of papules in the vicinity of the tumor, but he will be categorized as having a tumoral keloid.

OVERALL TREATMENT STRATEGY

A few basic facts need to be taken into consideration in treating all keloid patients, in particular patients with early-stage scalp keloids:

1. Involvement of scalp is a *dynamic process*. With passage of time, the disease will progress in all patients and will present itself by enlargement of existing lesions.
2. The disease process is *multifocal*. Quite often, patients will form new scalp lesions near the original site of the disease or distant from it.
3. Keloid disorder is a *disorder of the wound healing* response of the skin. It is the wounding of the skin that triggers formation of keloid lesions.

The most important steps in treating scalp keloids are:

- a. *To intervene very early* and to bring the disease under control with the combination of topical steroids and cryotherapy.
- b. *To avoid surgery* at all costs. Surgical removal of scalp keloids - a dynamic multifocal disease - is an inherently flawed approach that simply exposes patients to an unnecessary risk of developing massive tumoral keloids.
- c. *To avoid intra-lesional steroids*, as the injection contributes to a new injury within the keloid tissue that can potentially trigger worsening of the injected keloid.

EARLY-STAGE SCALP KELOIDS

Scalp keloids at their earliest stages appear in three distinct manners:

1. *Protruding papule(s)* is by far the most frequently observed form of early-stage scalp keloid. This has also been referred to as acne keloidalis (Figure 1).
2. *Linear lesion(s)* is a less common pattern of presentation of scalp keloid (Figure 2).
3. *Nodular lesions* that are due to natural progression of papular lesions (Figure 3).

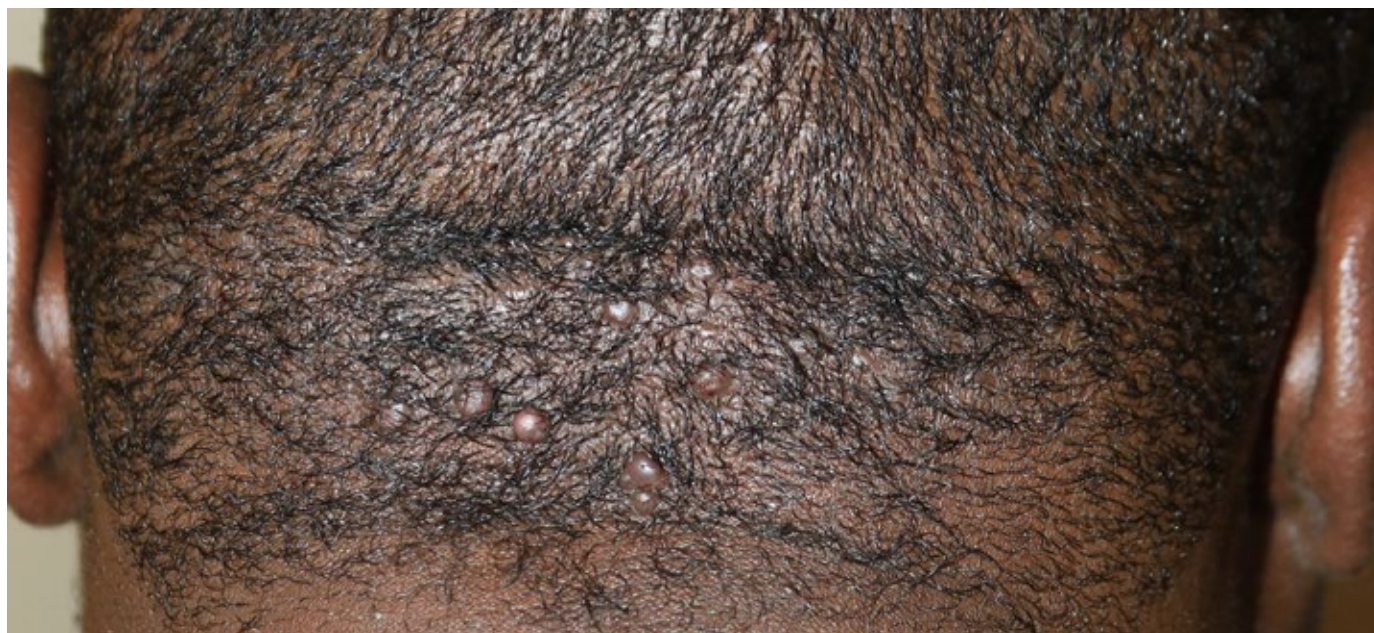

Figure 1. Early-stage involvement of scalp with keloid disorder presenting with several small protruding papules clustered in the occipital area. This patient also has multiple facial keloids that pre-dated the development of his scalp keloids.

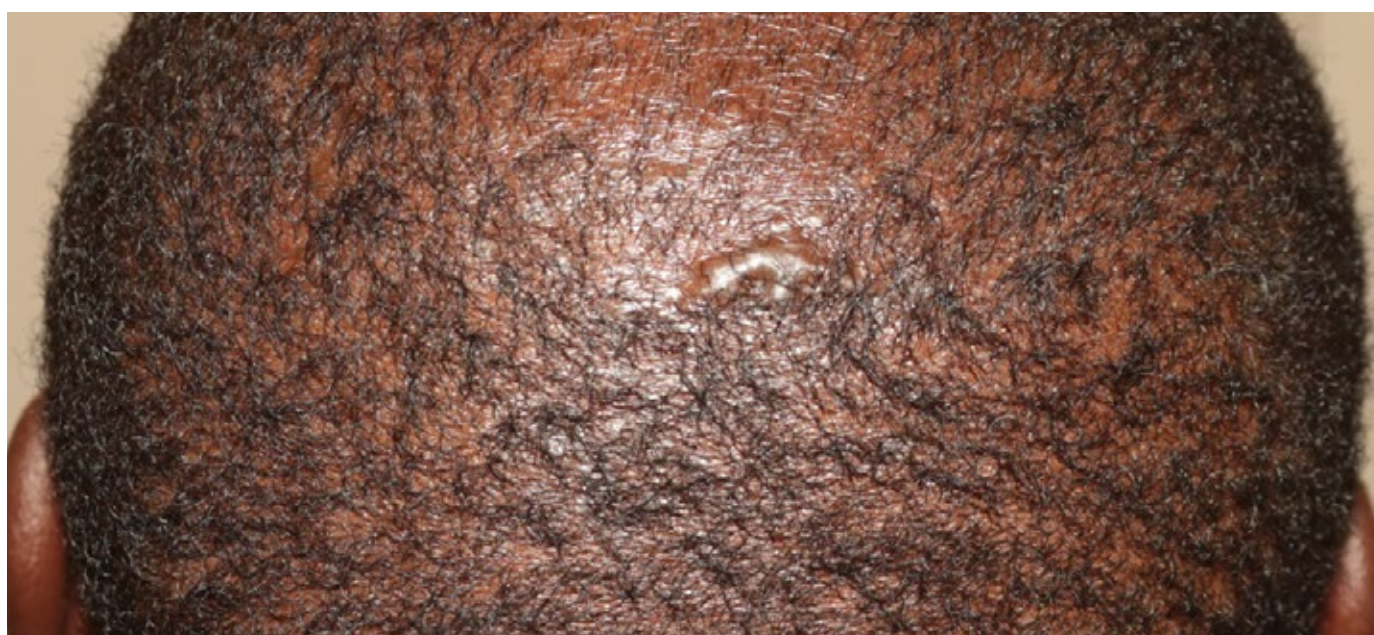

Figure 2. Early-stage involvement of scalp with keloid disorder presenting with a linear lesion in a 32-year-old male patient who has other keloid lesions on his face.

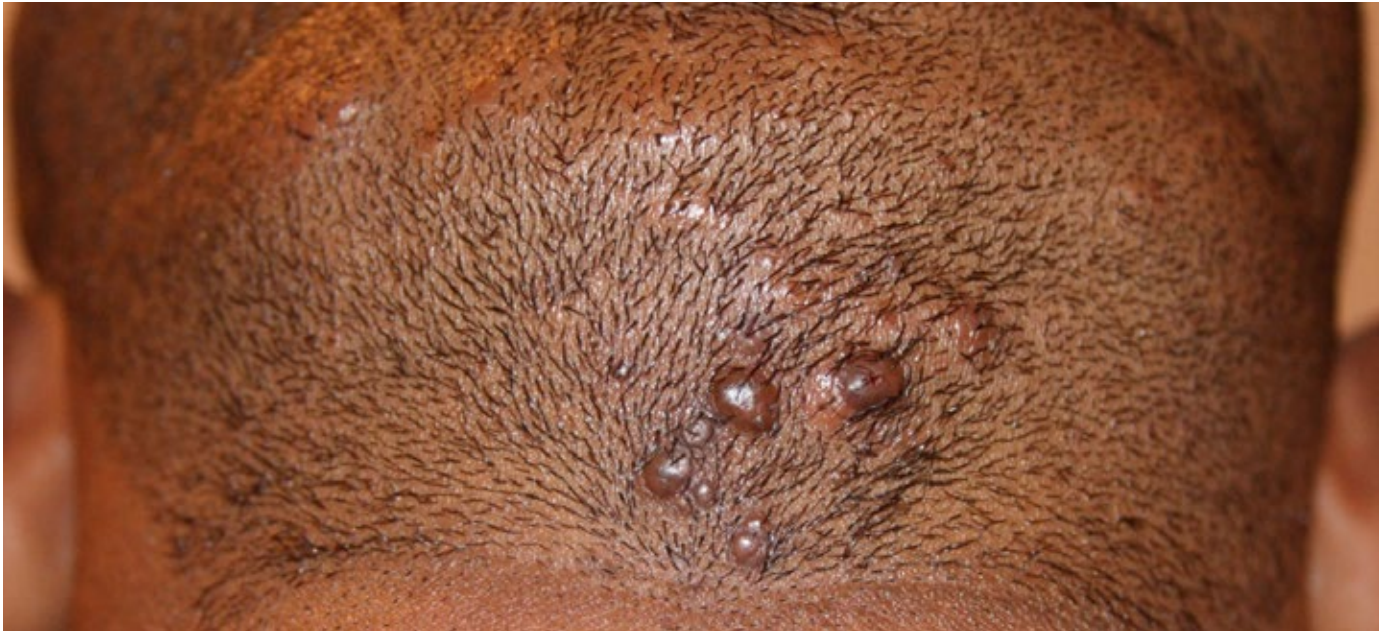

Figure 3. Early-stage involvement of occipital scalp with keloid disorder presenting with several small and large protruding papules, with some growing to become nodules.

Treatment

Goals of treatment for patients with early-stage scalp keloids are two-fold:

1. To induce remission.
2. To prevent progression and worsening of these keloids.

It is of utmost importance to properly manage patients with early-stage scalp keloids, so that formation of large and tumoral scalp keloids can be prevented. Keloid disorder has a dynamic pathology and with passage of time, patients are destined to develop many more keloid lesions, either on the scalp, or other (distant) parts of the skin. It is naïve to think that the disease has a static pathology and is limited to only one segment of the scalp, whereby it can be surgically removed.

Keloid disorder is a chronic ailment of the skin and quite often, its pathology involves much of the normal appearing skin. All patients shall be treated according to a long-term plan of care that includes ongoing follow-up and proper patient education.

Topical high-potency steroid lotions: Early-stage scalp keloids (Figures 1-3) shall be first treated with a topical high or ultra-high potency steroid lotion (betamethasone, clobetasol, etc.) for several weeks. During this time, the patient and the physician shall both monitor the lesions. If the lesions

respond to this intervention, one can safely continue with this treatment. Progression of keloids on this treatment will signal the necessity for cryotherapy.

Contact Cryotherapy: For early-stage keloid lesions that fail to respond to topical steroids or for prominent papules or nodules (Figures 1-3), contact cryotherapy is the next best option. Cryotherapy will often need to be repeated every 4-8 weeks, depending on the response to treatment, healing time as well as the durability of the response. Almost all compliant patients who are at this stage of their illness will respond to this simple intervention.

Surgery: Surgery shall NOT be used in treatment of scalp keloids. Keloid disorder has a dynamic and multifocal pathology; not one that is limited to a particular area of skin that can be surgically removed. Furthermore, surgery can trigger worsening of the treated keloids [1,2].

Intra-lesional triamcinolone injection: ILT shall be avoided as the intervention carries an inherent risk of worsening the keloid lesions [6].

Radiation therapy shall NOT be used in this setting. Radiation carries an inherent risk of causing secondary neoplasm [3, 4].

Lasers shall NOT be used in this setting. Lasers are also known to result in aggravation and worsening of keloid lesions [5].

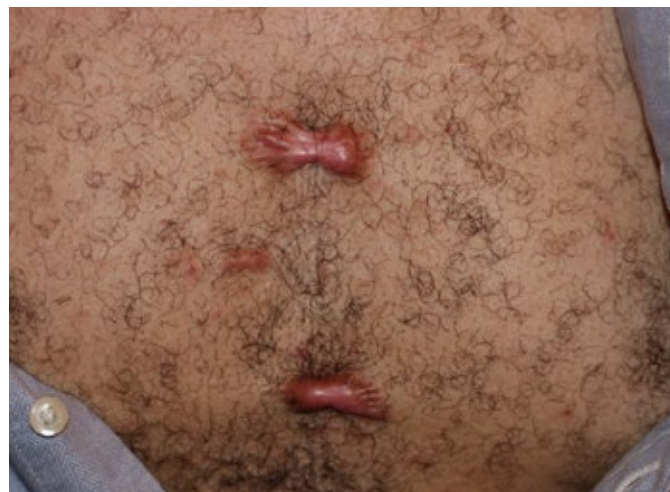
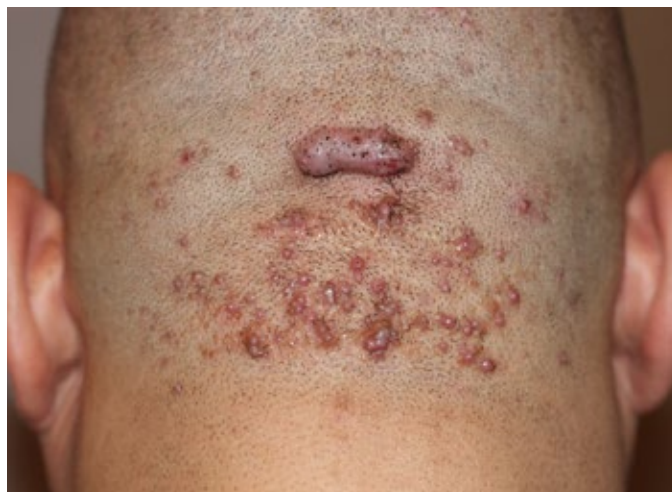
Figure 4. Locally-advanced scalp keloids in a 40-year-old male with numerous acne keloidalis lesions and multiple chest keloids.

LOCALLY-ADVANCED SCALP KELOIDS

With the passage of time, the keloid process progresses. This is evidenced by an increase in the number and size of keloid lesions, as well as merger of some lesions. Those who suffer from keloids elsewhere on their skin may also observe progression of their disease in other sites. Several examples are depicted in Figures 4-13.

Case Study 1

Figure 5 depicts a 35-year-old African American male who presented to the author in August 2013 with an infected scalp keloid. The scalp keloid process had started approximately ten years earlier. He had previously been treated with various scalp lotions and ILT. Subsequently, he had undergone scalp keloid removal surgery. This intervention was not curative and led to recurrence of the keloid process which became

worse than the original keloid. The recurrence was also complicated with frequent and unremitting infections, frequent oozing and bleeding. At the time of presentation in August 2013, besides having the infected occipital keloidal mass, there were several new prominent papules on his scalp and one in his upper posterior neck area. During his first visit, all visible and palpable keloid lesions, including the infected mass were treated with topical cryotherapy.

Upon recovery from the first cryotherapy, the keloid mass was noticeably smaller and all the chronic pre-existing oozing had stopped. Cryotherapy was repeated several times, and with each treatment, the mass of this keloid was further reduced. Figure 6 depicts the outcome of this treatment 17 months after the initial presentation. Ever since, the patient has been coming to our clinic once every 3-6 months for repeat cryotherapy of new or recurrent lesions.

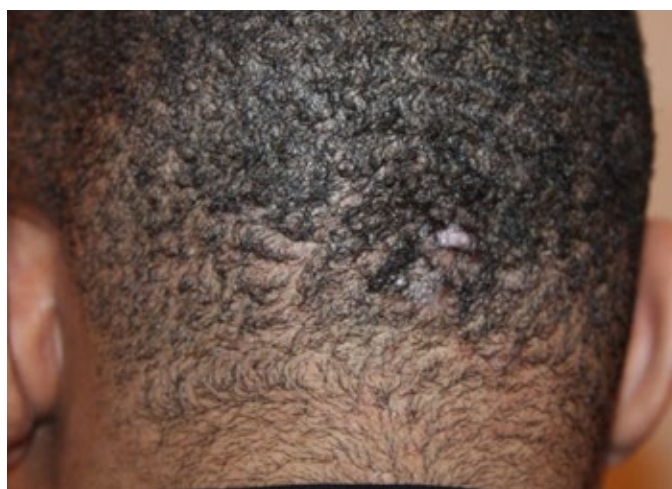


Figure 5. The same patient (as shown in Figure 5) 17 months later. In the interim, he was treated with several monthly applications of contact cryotherapy. The previously infected lesion is in partial remission now. The infection has fully subsided.

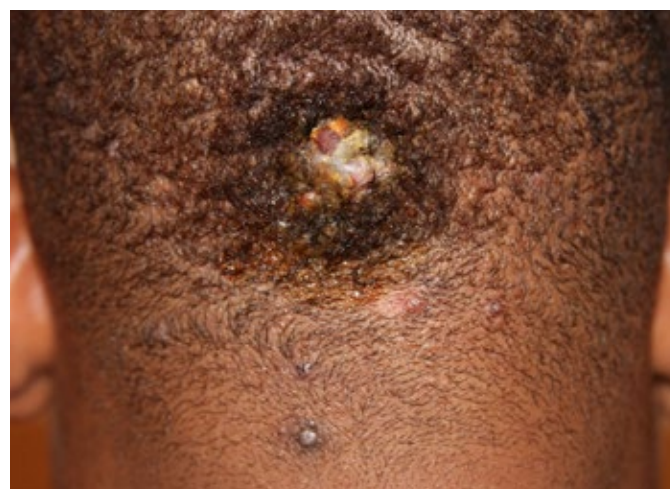

Figure 6. 35-year-old African American male with recurrent patch of scalp keloid following surgical removal of smaller scalp keloid lesions.

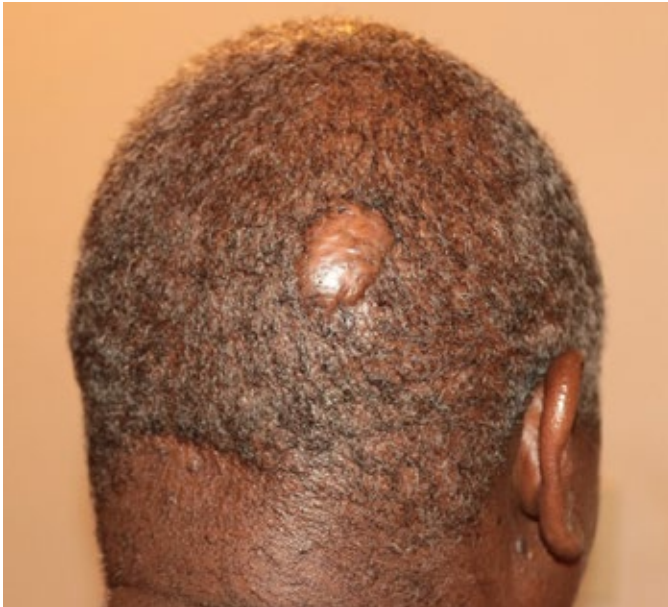

Figure 7. A 60-year-old male locally-advanced flat keloid patch of scalp. There was a 9 year history of scalp keloids and no other keloids elsewhere on his skin. The keloid had been previously treated with ILT but had continued to grow.

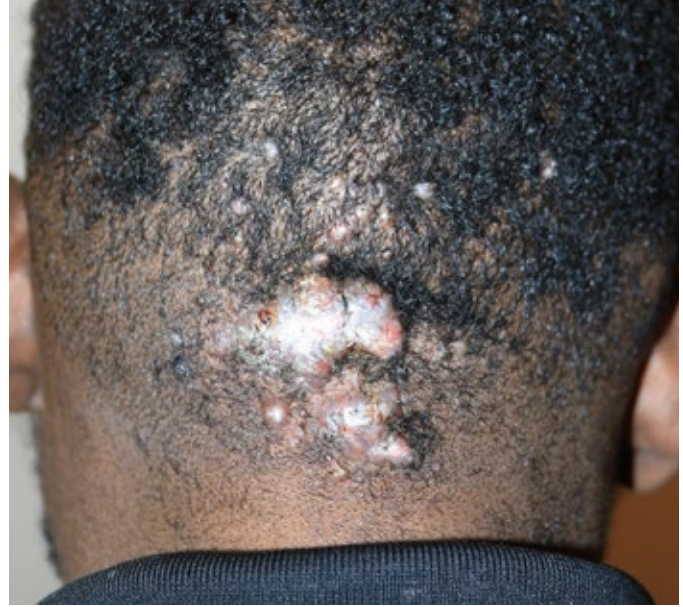

Figure 9. A 25-year-old male with a locally-advanced nodular form of upper neck, lower occipital keloid disorder. The keloid lesions had failed to respond to ILT.

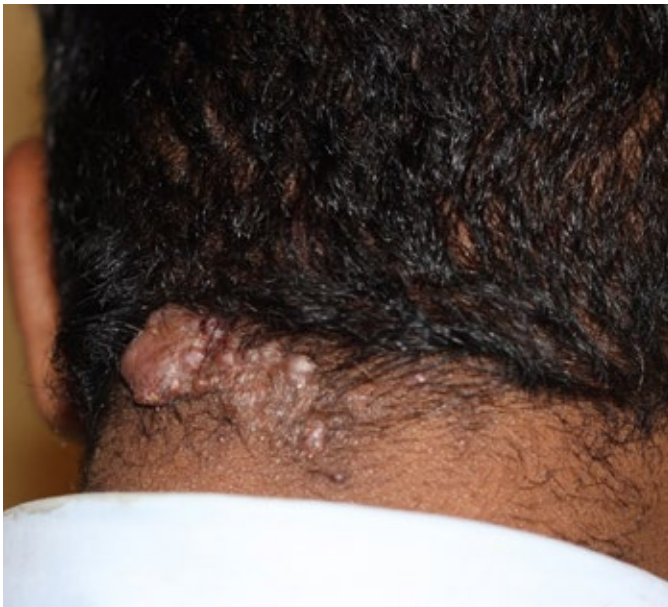

Figure 8. A 37-year-old male with a locally-advanced papular form of upper neck, lower occipital keloid disorder. The keloid had not responded to ILT. Cryotherapy and topical steroid lotions are the treatments of choice for this type of keloid.

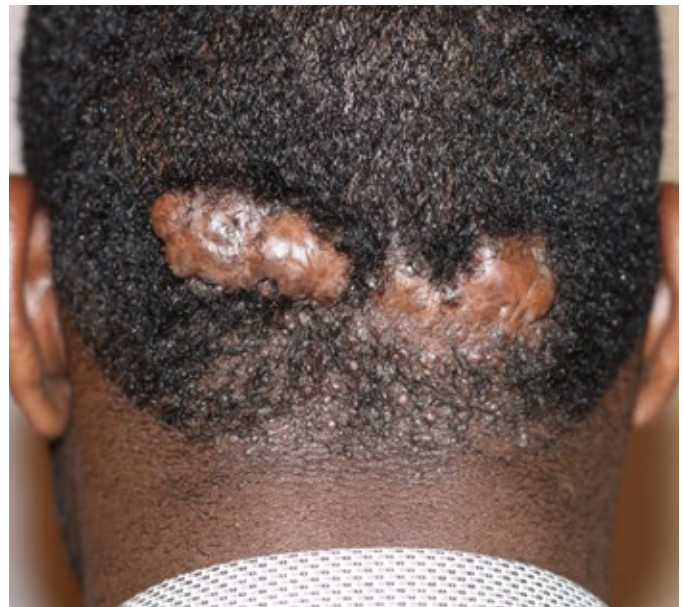

Figure 10. Locally-advanced flat occipital keloid lesions surrounded by numerous papular lesions. Treating the disease at this stage is rather challenging. Ideally, this occurrence should have been prevented with a rigorous early intervention program. Cryotherapy should be used to debulk the keloid masses. Topical steroid lotions should be used for treatments of papular component of the disease.

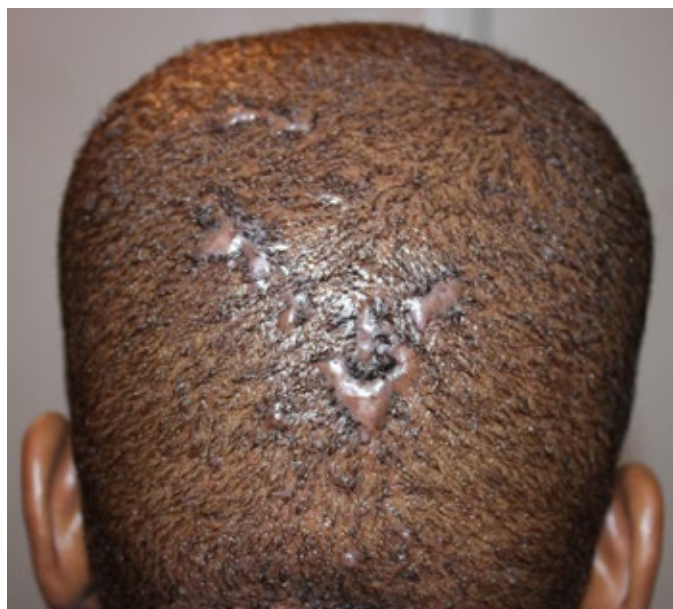

Figure 11. A 30-year-old male with superficially spreading, multifocal flat keloidal involvement of scalp. His scalp keloids had started at age 28 and had been treated with repeated ILT injections.

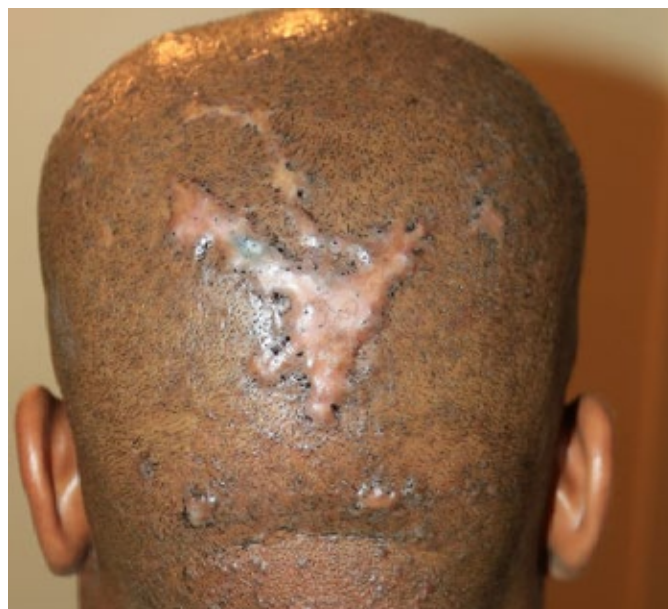

Figure 12. The same patient shown in Figure 11, three years later. The disease had progressed in all areas of his scalp.

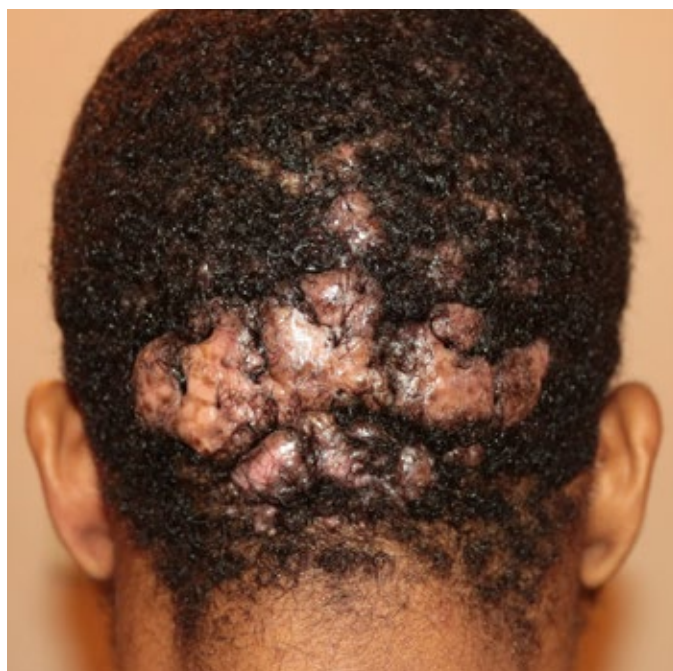

Figure 13. A 25-year-old male with widespread multinodular / tumoral keloidal involvement of scalp. His first scalp keloid had formed at age 20 for which he had received multiple ILT injections. Notice the multifocality of the disease process. Managing this type of scalp keloid is extremely difficult. Patients like this young man are in need of systemic treatments.

SCALP KELOID TUMORS

At times, scalp keloids can appear as solitary tumors with or without the accompanying acne keloidalis component. These tumors often interfere with the patient's ability to sleep as they get caught in the bed linens and sustain additional tissue injury which can lead to further worsening and growth of these tumors. The patient depicted in Figures 14-15 was a 31-year-old African American female with multiple very advanced keloid lesions on her face, chest, neck and extremities. The keloid depicted on her scalp was interfering with her ability to sleep. This keloid tumor was treated with cryotherapy. Figure 15 shows the result of treatment after one course of cryotherapy.

Cryotherapy is the treatment of choice for all bulky tumoral scalp keloids and the only method to be used in treating such keloids. As shown in Figures 16-19, surgery simply exposes patients to an unacceptable risk of developing massive scalp keloids.

If left untreated, or made worse by surgical intervention, scalp keloids may progress to form large tumors. Semi-massive and massive scalp keloids are almost exclusively seen in African American men. Most these patients have previously undergone scalp keloid removal surgery. Among 54 patients that were seen by the author, there were 9 patients with massive scalp keloids, 7 of whom had undergone prior keloid removal surgeries.

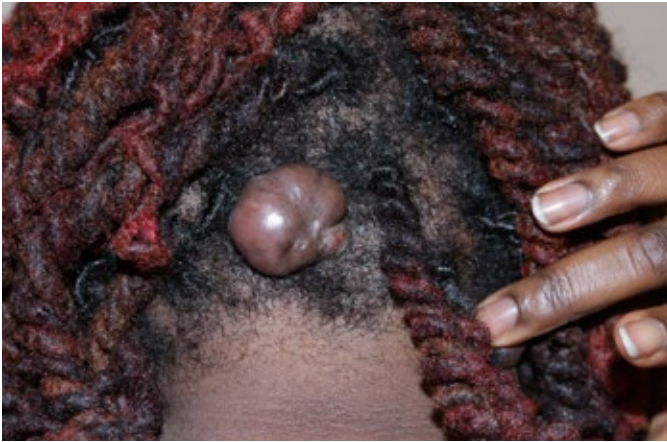

Figure 14. Tumoral scalp keloid in a 31-year-old African American female

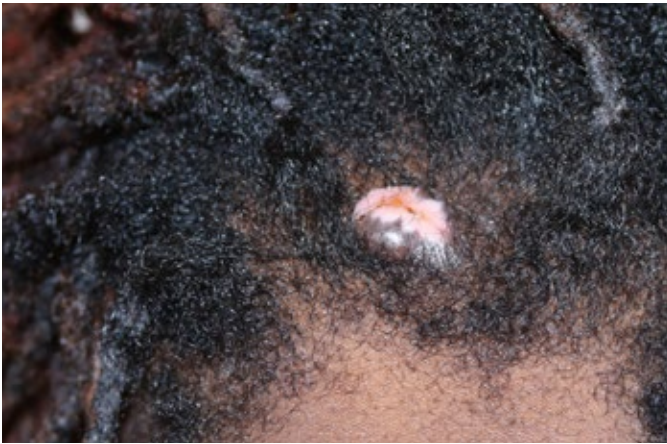

Figure 15. The same patient shown in Figure 14 one month after application of cryotherapy. Significant debulking was achieved with a simple out-patient procedure. With repeated cycles of cryotherapy, the lesion will further improve. Partial reduction in the mass of the keloid tumor was enough to allow this patient to sleep better at night.

Surgical Case Studies

Figure 16 depicts a 30-year-old African American male with a 6 year history of developing scalp keloids. His first scalp keloid formed when he was 24 years of age. Over the years, he underwent several surgical excisions followed by radiation therapy to remove several keloids from his scalp, all with the hope of eradicating his scalp keloids. Figure 15 depicts the status of his recurrent scalp keloids, most of which are tumoral. Neither surgeon's scalpel nor radiation therapy can overcome the challenging and multifocal biology of this disease. Quite often, these efforts unfortunately result in a much worse outcome, one that with today's available tools is rather impossible to remedy.

Figure 17 depicts a 31-year-old African American male with diffuse keloidal involvement of the scalp. His first scalp keloid formed at age 25 in the lower occipital area. He was treated with ILT first and then surgery followed by radiation therapy. Unfortunately, the keloid process

advanced despite all these treatments. Treating patients like him is very difficult. Our aim shall be to avoid causing such worsening of keloids by using invasive procedures.

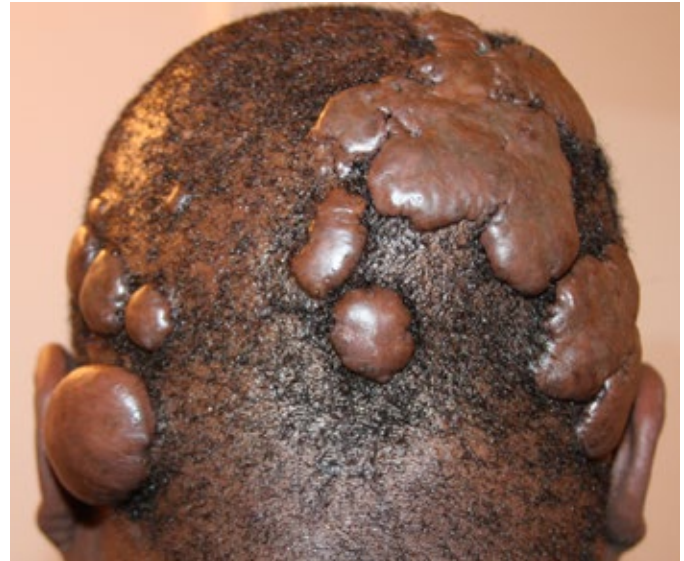

Figure 16. A 30-year-old African American male with multiple tumoral keloids of the scalp.

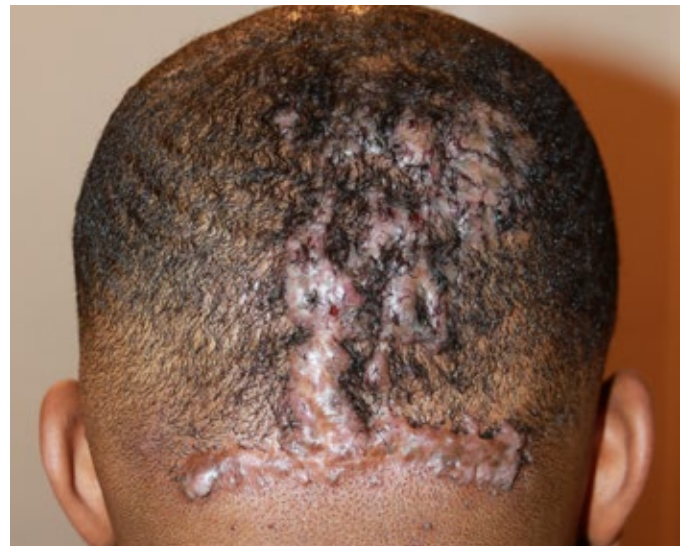

Figure 17. A 31-year-old African American male with diffuse keloidal involvement of the scalp which was made worse after keloid removal surgery

Figure 18 depicts a 40-year-old male who presented with multifocal keloidal involvement of the scalp. His scalp keloid had first formed six years earlier. He had been treated with ILT, then surgery followed by radiation therapy. Despite all these efforts, a massive keloid had formed at the site of his last surgery. It is needless to say that treating patients who present with such advanced scalp keloids is very challenging.

Figure 19 depicts a 43-year-old-male with multifocal keloidal involvement of the scalp. His first scalp keloid had formed twelve years earlier. He had been treated with

multiple rounds of ILT and multiple attempts at surgical resection of his scalp keloids.

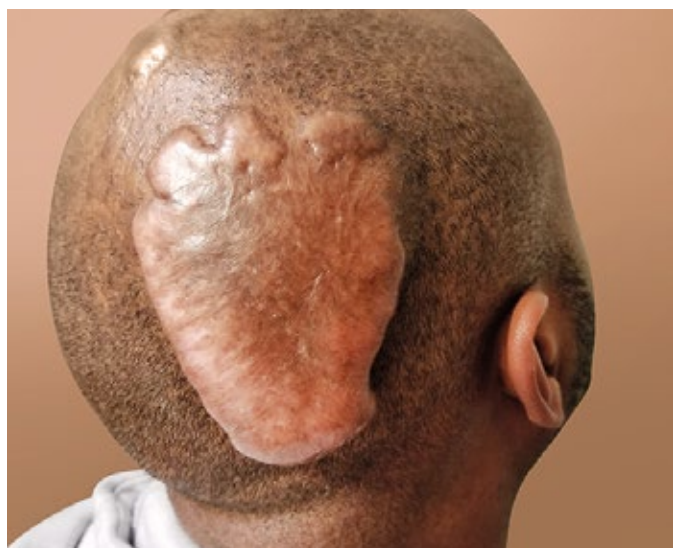

Figure 18. A 30-year-old male with superficially spreading, multifocal flat keloidal involvement of scalp. His scalp keloids had started at age 28 and had been treated with repeated ILT injections.

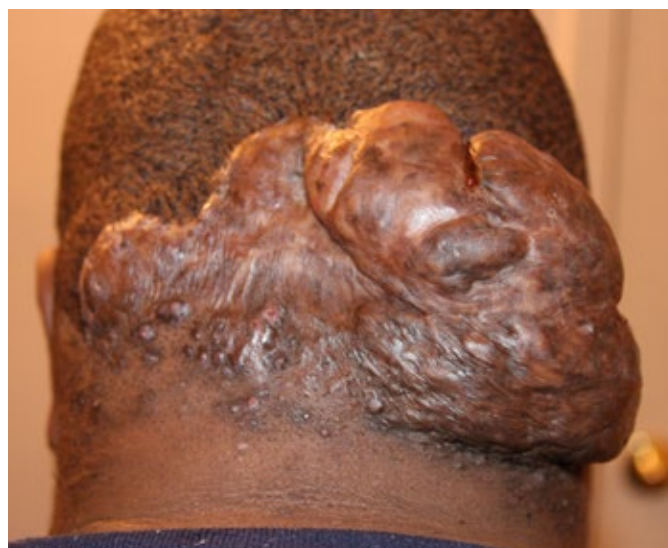

Figure 19. The same patient shown in Figure 11, three years later. The disease had progressed in all areas of his scalp.

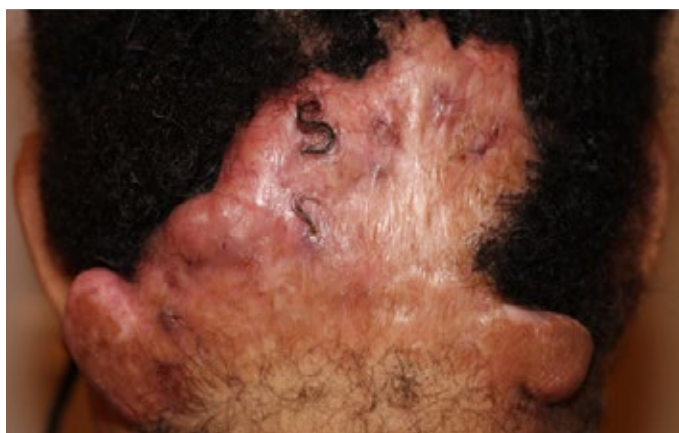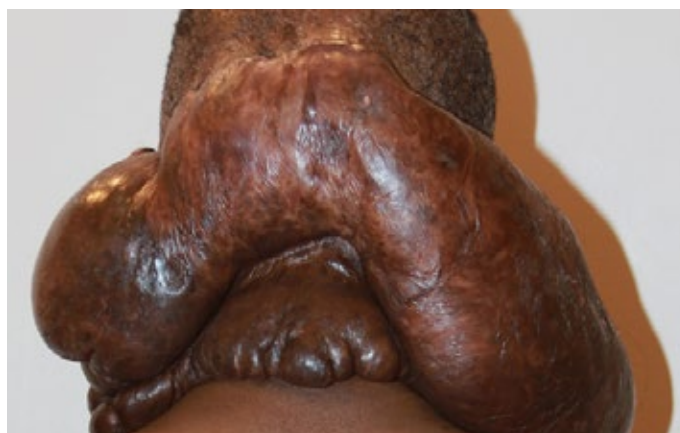

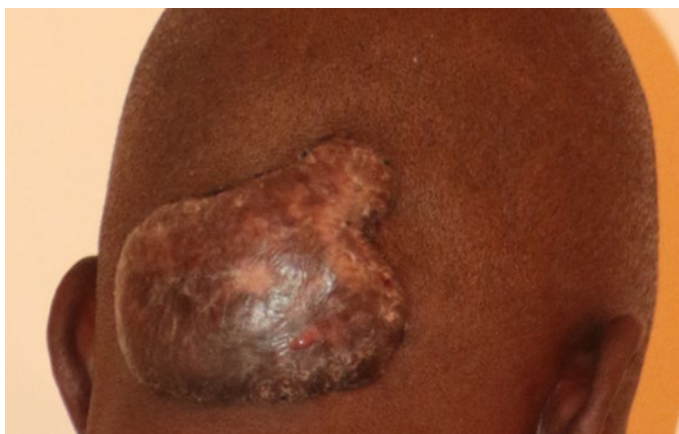
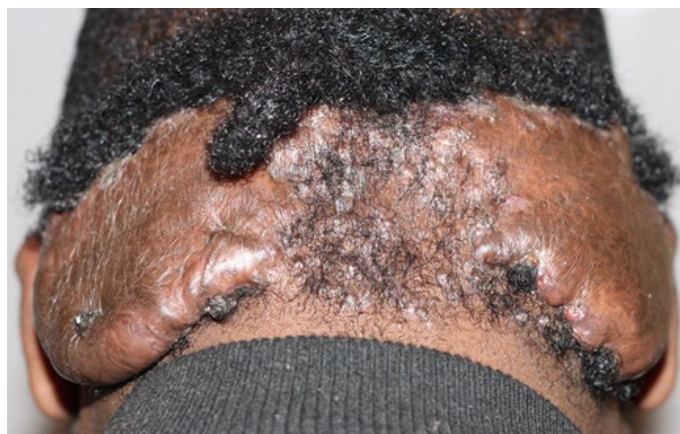Figure 20. Several more examples of massive and a case of super-massive tumoral keloids in patients who had had prior surgery for removal of smaller scalp keloids.

REFERENCES

1. Tirgan, MH. Neck keloids: evaluation of risk factors and recommendation for keloid staging system, F1000 Research, June 28, 2016
2. Tirgan, MH. Massive ear keloids: Natural history, evaluation of risk factors and recommendation for preventive measures – A retrospective case series, F1000 Research, October 13, 2016
3. Miyahara H, Sato T, Yoshino K. Radiation-induced cancers of the head and neck region. Acta Otolaryngology Suppl. 1998;533:60-4
4. Ron E. Cancer risks from medical radiation. Health Phys. 2003 Jul;85(1):47-59.
5. Tirgan, MH. Laser Treatment of Keloid Lesions, Efficacy and Side Effects, Results of an on-line survey .Abstract – 2nd International Keloid Symposium, Rome, Italy June 7-8 2018. Full manuscript in press.
6. Tirgan, MH. Intra-lesional Steroid Injections: Can they be harmful to some patients? Results of an online survey. International Journal of Keloid research. 2017 vol. 1 no. 1, July 1, 21-28